

Australian Association of Vaginal and Incontinence Surgeons (AAVIS)  
 Keynote Speaker: Jacques Beco M.D.  
 How can we win the war against pudendal neuropathy ?

Venice (Italy) 3rd October 2008

**10<sup>th</sup> AAVIS Annual Scientific Meeting**  
**International Pelviperineology Congress**  
**AAVIS-ICOPF-IPFDS Joint Meeting**

**How can we win the war against pudendal neuropathy ?**

Jacques Beco M.D.  
 Liège University Belgium  
[www.perineology.com](http://www.perineology.com)  
[www.pudendal.com](http://www.pudendal.com)

**Question:**  
 How can we win the war against pudendal neuropathy ?

**Answer:**  
 Be open mind; don't forget to think « pudendal »

**Pudendal neuralgia**  
**First publication**

G. Amarenco, Y. Lanoe, H. Goudal, M. Perrigot  
*La compression du nerf honteux interne dans le canal d'Alcock ou paralysie périnéale du cycliste. Un nouveau syndrome canalaire.*


Presse Med. (1987), 8, 399.

**Surgery of pudendal neuralgia**  
**First publication**

R. Robert, JJ Labat, PA Lehur, P. Glemain, O. Armstrong, J. Le Borgne, JY Barbin  
*Réflexions cliniques, neurophysiologiques et thérapeutiques à partir de données anatomiques sur le nerf pudendal (honteux interne) lors de certaines algies périnéales.*

Chirurgie (1989), 115, 515-520.

**Pudendal canal syndrome**  
**First perineological approach**



A. Shafik  
*Pudendal canal syndrome. Description of a new syndrome and its treatment. Report of 7 cases*

Coloproctology (1991), 13, 102-110.

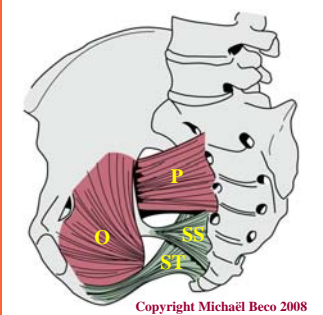
**What is the name of our enemy ?**

<b>Pudendal neuropathy</b>				
<table border="1"> <tr> <td><b>Pudendal nerve entrapment (entrapment only)</b></td> </tr> <tr> <td> <table border="1"> <tr> <td><b>Pudendal canal syndrome (Alcock's canal only)</b></td> </tr> <tr> <td><b>Pudendal neuralgia (pain only)</b></td> </tr> </table> </td> </tr> </table>	<b>Pudendal nerve entrapment (entrapment only)</b>	<table border="1"> <tr> <td><b>Pudendal canal syndrome (Alcock's canal only)</b></td> </tr> <tr> <td><b>Pudendal neuralgia (pain only)</b></td> </tr> </table>	<b>Pudendal canal syndrome (Alcock's canal only)</b>	<b>Pudendal neuralgia (pain only)</b>
<b>Pudendal nerve entrapment (entrapment only)</b>				
<table border="1"> <tr> <td><b>Pudendal canal syndrome (Alcock's canal only)</b></td> </tr> <tr> <td><b>Pudendal neuralgia (pain only)</b></td> </tr> </table>	<b>Pudendal canal syndrome (Alcock's canal only)</b>	<b>Pudendal neuralgia (pain only)</b>		
<b>Pudendal canal syndrome (Alcock's canal only)</b>				
<b>Pudendal neuralgia (pain only)</b>				

Australian Association of Vaginal and Incontinence Surgeons (AAVIS)  
 Keynote Speaker: Jacques Beco M.D.  
 How can we win the war against pudendal neuropathy ?

### Anatomy of the pudendal nerve

#### Lesser sciatic foramen

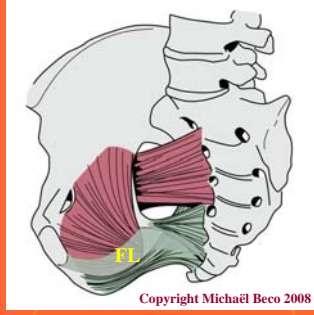


SS = Sacro-spinal ligament  
 ST = Sacro-tuberous ligament  
 O = Obturator muscle between the 2 ligaments (lesser sciatic foramen)  
 P = Piriformis muscle (greater sciatic foramen)

Copyright Michaël Beco 2008

### Anatomy of the pudendal nerve

#### Fascia lunata



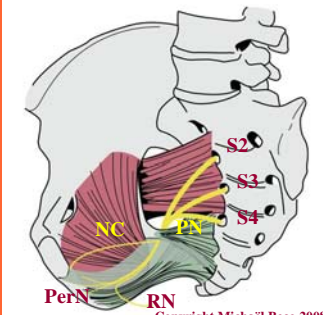
FL = The fascia lunata closes the lesser sciatic foramen (space between the 2 ligaments)

Derry DE: Pelvic muscles and fasciae. *Journal of Anatomy and Physiology* 1907, 42:107-111.

Copyright Michaël Beco 2008

### Anatomy of the pudendal nerve

#### Pudendal nerve



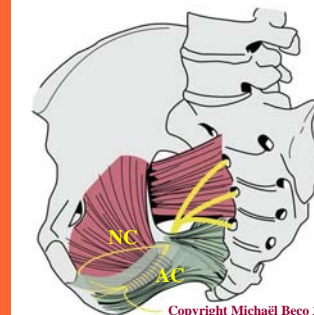
NC = Nerve of the clitoris or penis  
 RN = Rectal nerve sometimes in the sacro-spinal ligament  
 PerN = Perineal nerve: 3 branches  
 PN = Typical fascicular disposition of the pudendal nerve

Gustafson KJ, Zelkovic PF, Feng AH, Draper CE, Bodner DR, Grill WM: Fascicular anatomy and surgical access of the human pudendal nerve. *World J Urol* 2005, 23(6):411-418.

Copyright Michaël Beco 2008

### Anatomy of the pudendal nerve

#### Alcock's or pudendal canal

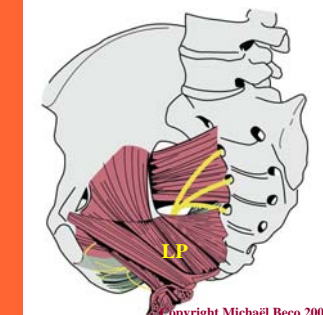


NC = Nerve of the clitoris or penis not in the Alcock's canal (AC)

Copyright Michaël Beco 2008

### Anatomy of the pudendal nerve

#### Levator plate and puborectalis



90% of the pudendal nerve is under the levator plate (LP)

Copyright Michaël Beco 2008

### Fascia lunata

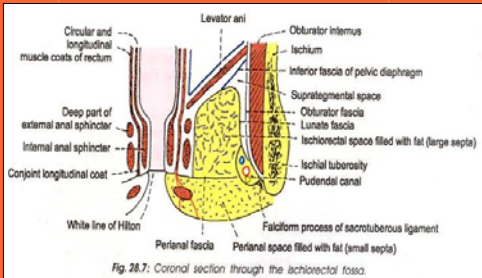
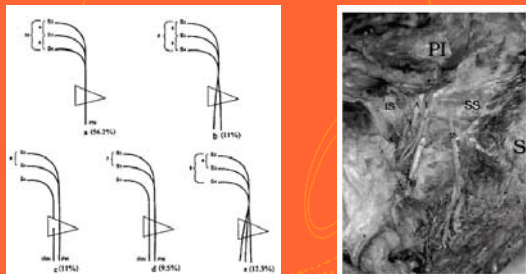


Fig. 28.7: Coronal section through the ischio-rectal fossa.

Image from: [http://www.indiasurgeons.com/lectures/ischio\\_rectal\\_fossa.htm](http://www.indiasurgeons.com/lectures/ischio_rectal_fossa.htm)  
 « Applied Anatomy of Ischio-rectal fossa and Pelvic Floor » Dr.Barin Bose Jabalpur (MP)

Australian Association of Vaginal and Incontinence Surgeons (AAVIS)  
 Keynote Speaker: Jacques Beco M.D.  
 How can we win the war against pudendal neuropathy ?

**Rectal nerve passing through the sacro-spinal ligament in 11% of the cases**




Mahakkanukrauh P, Surin P, Vaidhayakam P  
**Anatomical study of the pudendal nerve adjacent to the sacrospinal ligament.**  
*Clin Anat* 2005, **18**(3):200-205.

**Pudendal neuropathy**  
 The symptoms

Classical (Shafik)	Others ??
1. Perineodynia (pain): - pudendal neuralgia - vulvodinia - proctalgia fugax	1. Dyschesia
2. Anal incontinence	2. Dysuria
3. Stress urinary incontinence	3. Dyspareunia
4. Impotence	4. Painful bladder
5. Perineal hypo or dysesthesia	5. Urge incontinence, frequency, urgency, nocturia
	6. Painful ejaculation, « prostatitis »
	7. Sexual arousal syndrome
	8. Skin anomalies (cutis anserina...)
	9. ????????

**How can we win the war against pudendal neuropathy ?**

Easy evaluation of the main symptoms with the TAPE



Beco J: The T.A.P.E. (Three Axes Perineal Evaluation) freeware: a good tool to introduce you to Perineology.  
*Pelvipereineology* 2008, **27**(1):29-30.

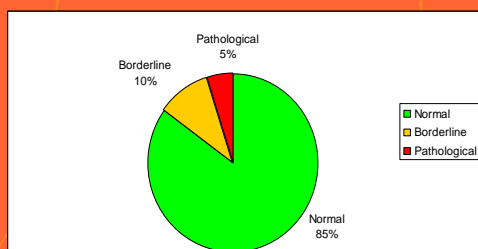
**Pudendal Neuropathy**

Normal => Pathological or Borderline

Distortion of the « chassis »	Repetitive trauma
1. Fall on the coccyx	1. Job with long time sitting or wrong sitting position (pianist, programmer...)
2. Impact on the spine or on the pelvis (car or motorbike accident...)	2. Biking
3. Heavy lifting	3. Long car or airplane travels
4. Heavy osteopathic manipulation	
5. Traction for lower limbs orthopedic surgery	
Traction on the nerves	Other causes
1. Dyschesia and DPS	1. Polyneuropathy (diabetes, alcool...)
2. Childbirth	2. Congenital ??
3. Vaginal surgery (retractors)	3. Vaginal surgery (direct lesion)

**Pudendal neuropathy**

Estimated prevalence  
 => very frequent defect



**Pudendal neuropathy**  
 Flare up hypothesis for pain  
 Borderline => pathological

1. Longo's procedure (8 cases of severe perineodynia !)
2. Bartholin's cyst surgery
3. Hemorrhoids surgery
4. Colonoscopy
5. Laparoscopy
6. Vaginal surgery
7. Others « agressions » in this area

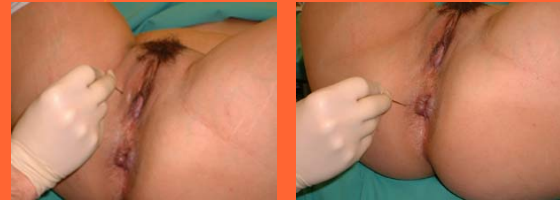Australian Association of Vaginal and Incontinence Surgeons (AAVIS)  
Keynote Speaker: Jacques Beco M.D.  
How can we win the war against pudendal neuropathy ?

## Pudendal neuropathy

Tracking #1 => three clinical signs

1. Perineal hypo or hyperesthesia (pinprick)
2. Painful pudendal nerve during rectal examination
3. Painful « skin rolling test » of the perineal skin

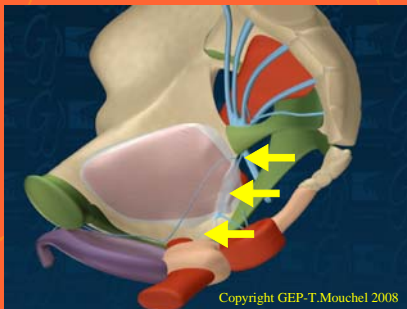
## Pinprick sensibility test



Vulvar

Para-Anal

## Painful pudendal nerve



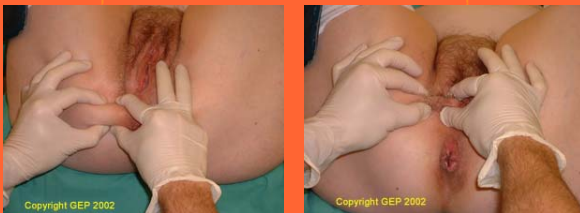Copyright GEP-T.Mouchel 2008

## Painful pudendal nerve (rectal examination)

1. Mild
2. Mild with Tinel sign (irradiation)
3. Moderate
4. Moderate with Tinel sign
5. Severe
6. Severe with Tinel sign

Painful pudendal nerve if at least 4/6

## Skin Rolling Test



Copyright GEP 2002

Copyright GEP 2002

## Validation of the 3 clinical signs of pudendal neuropathy

### Control group

82 female patients  
mean age: 48,8 years (27-76)  
without prolapse  
without anal incontinence  
without perineodynia  
without an history of pelvi-perineal surgery

=> This control group was compared with a group of 74 patients before pudendal nerve decompression

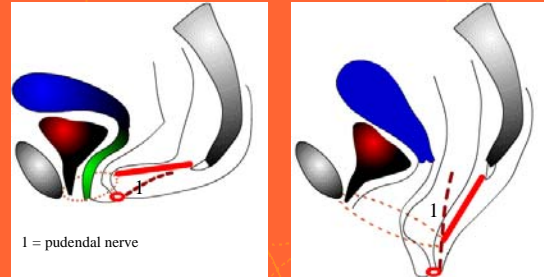
Australian Association of Vaginal and Incontinence Surgeons (AAVIS)  
 Keynote Speaker: Jacques Beco M.D.  
 How can we win the war against pudendal neuropathy ?

Validation of the 3 clinical signs of pudendal neuropathy (prevalence 20%)

Test	Sens	Spec	PPV	NPV	OR	95%CI OR
Abnormal sensibility	0.57	0.77	0.38	0.88	<b>4.42</b>	1.99 - 9.82
Painful pudendal nerve	<b>0.70</b>	0.71	0.37	0.90	<b>5.52</b>	2.51 - 12.15
Painful skin rolling test	0.55	<b>0.84</b>	0.47	0.89	<b>6.56</b>	2.74 - 15.68
The 3 (3 neg versus 3 pos)	0.68	<b>0.89</b>	0.60	0.92	<b>16.97</b>	4.68 - 61.51

Beco J, Climov D, Bex M  
 Pudendal nerve decompression in perineology : a case series.  
*BMC Surg* 2004, 4(1):15.

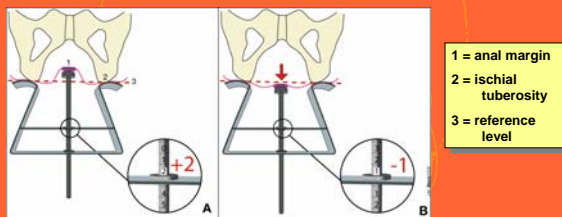
Pudendal neuropathy  
 Tracking #2 => DPS



Normal

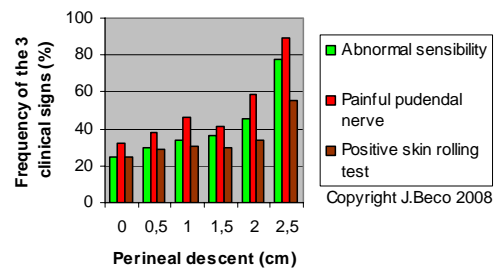
Descending Perineum

Measure of perineal descent with the Perineocaliper®



Beco J.: Interest of retro-anal levator plate myorrhaphy in selected cases of descending perineum syndrome with positive anti-sagging test.  
*BMC Surg* 2008, 8(1):13.

Frequency of the 3 clinical signs of pudendal neuropathy according to the perineal descent measured with a perineocaliper (n=820)



Copyright J.Beco 2008

Target population ?

1. Patient with one or more symptoms of pudendal neuropathy :

- perineodynia (pain while sitting, proctalgia fugax, vulvodynia...)
- urinary incontinence (! Fixed bladder neck !)
- painful bladder
- anal incontinence (! Intact anal sphincter !)
- troubles of the penis, vagina or clitoris sensibility
- impotence, painful ejaculation, « abacterial prostatitis »
- sexual arousal syndrome

2. Patient with a perineal descent > 1.5 cm

Pudendal neuropathy  
 Confirmation of the diagnosis

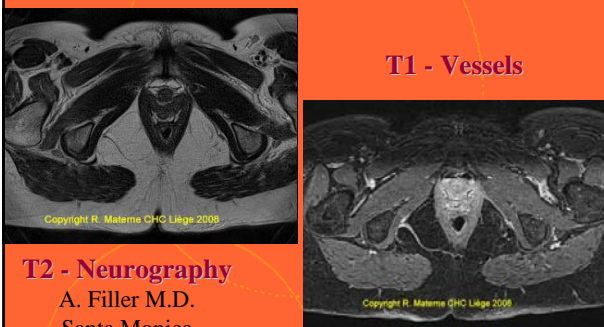
Function of the nerve

Fibers	Tests
Motor fibers	EMG => axonal loss PNTML => demyelination
A beta fibers	Pinprick test
A delta fibers	Cold detection threshold
C fibers	Warm detection threshold (S. Antolak M.D., Minneapolis)



Australian Association of Vaginal and Incontinence Surgeons (AAVIS)  
 Keynote Speaker: Jacques Beco M.D.  
 How can we win the war against pudendal neuropathy ?

### Anatomy of the nerve by MRI



**T1 - Vessels**

**T2 - Neurography**  
 A. Filler M.D.  
 Santa Monica

### Doppler of pudendal arteries

1. Compression of the artery => compression of the nerve  
 Nundlall R., <http://www.perineology.com/files/doppler-nundlal.pdf>
2. Compression of the artery => erectile dysfunction => pudendal nerve decompression improves vascularisation of the penis  
 Shafik A. Pudendal artery syndrome with erectile dysfunction: treatment by pudendal canal decompression. Arch Androl. 1995 Mar-Apr;34(2):83-94. )

### Main differential diagnosis

History and clinical examination	Other exams
<ol style="list-style-type: none"> <li>1. Levator plate sagging (DPS)</li> <li>2. Muscle trigger points</li> <li>3. Sacral roots lesion</li> <li>4. Other neuralgias (A-G, G-C, inferior cluneal, obturator...)</li> <li>5. Psychological distress</li> <li>6. Coccygodynia</li> <li>7. Back mouse</li> <li>8. Pyramidal syndrome</li> <li>9. Multiple sclerosis or other central lesions</li> <li>10. Polyneuropathy</li> <li>11. Urological, gynaecological or colo-proctologic disease</li> </ol>	<ol style="list-style-type: none"> <li>1. Lombo-sacral MRI and EMG: conus terminalis and sacral roots lesions</li> <li>2. Ultrasound: perineal descent, rupture of anal sphincter, bladder neck descent, prolapse</li> <li>3. Manometry: urinary and anal incontinences, frequency, painful bladder...</li> <li>4. Colpocystodefecography: rectal prolapse</li> <li>5. Blood sample</li> </ol>


### Treatment of pudendal neuropathy: curative

Lifestyle changes => protection of the nerve

1. Avoid sitting for long time if it is painful (use special chairs or U-shaped cushions) (S. Antolak M.D.)
2. Avoid biking
3. Avoid heavy lifting
4. Avoid childbirth, prefer cesarian section
5. Treat dyschesia and DPS (! Move back on the toilet seat !)

### Treatment of pudendal neuropathy: curative

Protection of the nerve



U-shaped cushion

Move back on the toilet seat

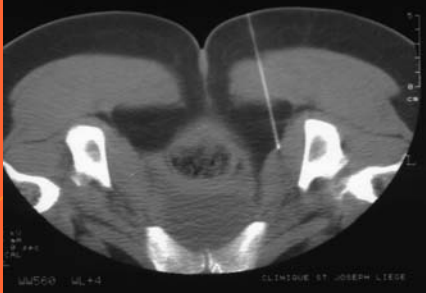
### Treatment of pudendal neuropathy: curative

Physiotherapy

DPS, incontinences and prolapses => contraction	Perineodynia (pain) => relaxation
<ol style="list-style-type: none"> <li>1. Kegel's exercises</li> <li>2. Biofeedback</li> <li>3. Electrostimulation</li> </ol>	<ol style="list-style-type: none"> <li>1. Manual therapy (J. Weiss)                             <ul style="list-style-type: none"> <li>- myofacial trigger point release</li> <li>- neural mobilization</li> <li>- connective tissue manipulation</li> </ul> </li> <li>2. Trigger point injections / dry needling (J. Weiss)</li> <li>3. Cold laser, TENS, magnets</li> </ol>


Australian Association of Vaginal and Incontinence Surgeons (AAVIS)  
 Keynote Speaker: Jacques Beco M.D.  
 How can we win the war against pudendal neuropathy ?

**Treatment of pudendal neuropathy: curative**  
**Infiltration under scanner control**  
 (or ultrasound or electrostimulation or finger control)



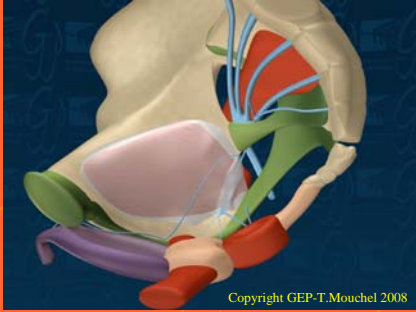
Images from JF Biquet M.D., CHC Saint Joseph, Liège

**After infiltration**



Images from JF Biquet M.D., CHC Saint Joseph, Liège

**Treatment of pudendal neuropathy: curative**  
**Surgery**




Copyright GEP-T.Mouchel 2008

**Five surgical procedures**


<b>Complete decompression</b>
<ol style="list-style-type: none"> <li>1. Transgluteal (Robert 1990)</li> <li>2. Transperineal:                     <ul style="list-style-type: none"> <li>- with digitoclasy of fascia lunata (Beco 2006)</li> <li>- with sacro-spinal ligament section (Shafik 2007)</li> </ul> </li> </ol>
<b>Incomplete decompression</b>
<ol style="list-style-type: none"> <li>1. Transperineal without « clamp » opening (Shafik 1991)</li> <li>2. Trans-ischiorectal (Bautrant 2003)</li> <li>3. Laparoscopic (??)</li> </ol>

**Transgluteal procedure**  
**(Robert 1990)**  
**Incision**



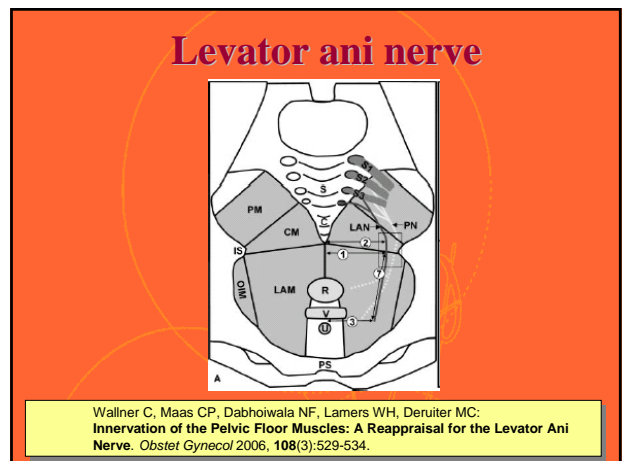
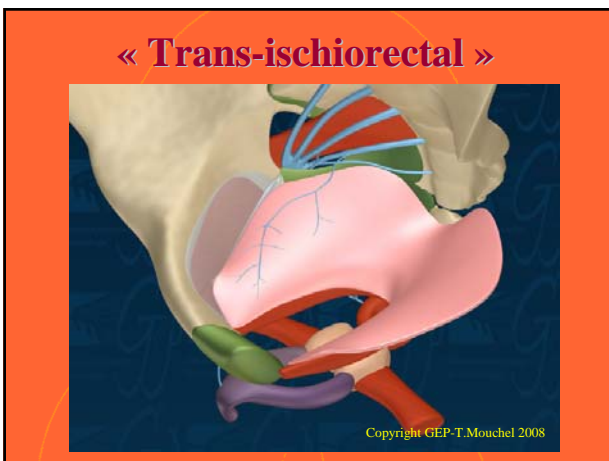
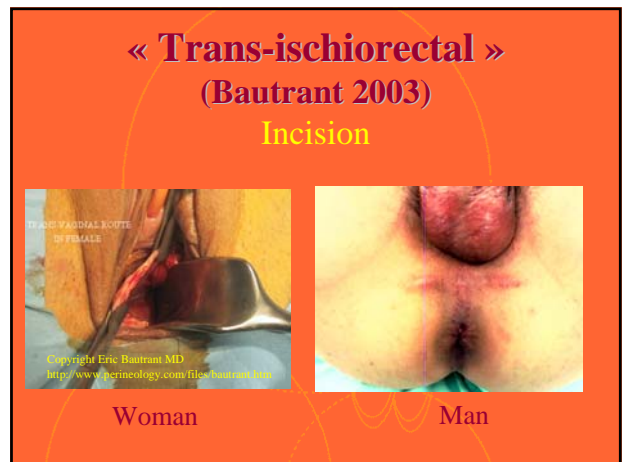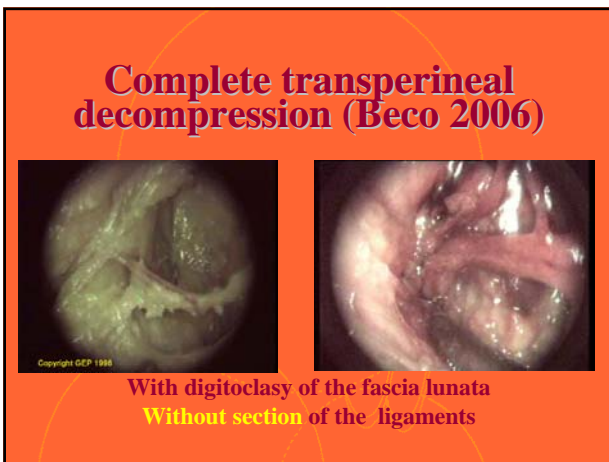
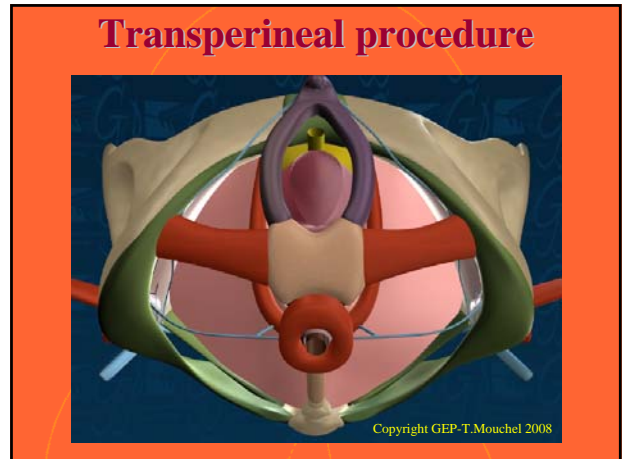
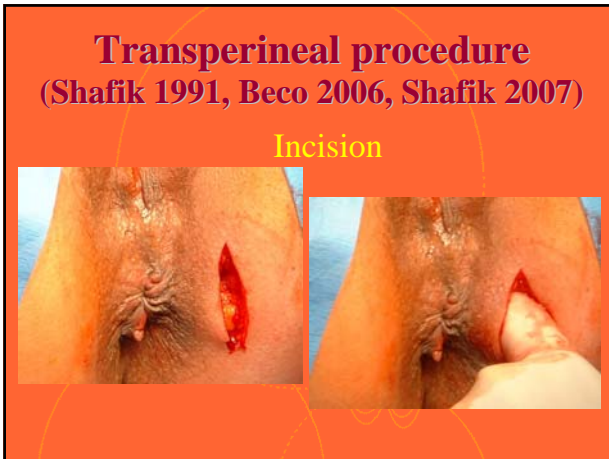Copyright R. Robert

**Transgluteal procedure**



Copyright GEP-T.Mouchel 2008

Australian Association of Vaginal and Incontinence Surgeons (AAVIS)  
 Keynote Speaker: Jacques Beco M.D.  
 How can we win the war against pudendal neuropathy ?





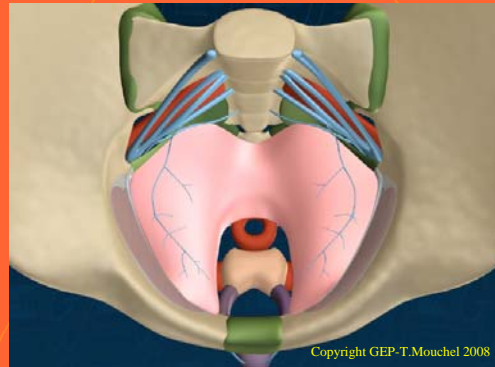
Australian Association of Vaginal and Incontinence Surgeons (AAVIS)  
 Keynote Speaker: Jacques Beco M.D.  
 How can we win the war against pudendal neuropathy ?

## Laparoscopic procedure

1. No clinical data available
2. One study on cadavers

Loukas M, Louis RG, Jr., Tubbs RS, Wartmann C, Colborn GL:  
**Intra-abdominal laparoscopic pudendal canal decompression - a feasibility study.** *Surg Endosc* 2008, **22**(6):1525-1532.

## Laparoscopic procedure



### Which approach is the best ?

Approaches	Trans-perineal	Trans-gluteal	Trans-ischiorectal
Incision	Short	<b>Large</b>	Short
Visual control	No	Yes	No
Access to entire length Alcock's canal	Yes +++	Yes ++	<b>No</b>
Ligament section(s)	Yes (Shafik 2007) No (Beco 2006)	<b>Complete</b>	Partial
« Clamp » opening	Yes ++ (No; Shafik 1991)	Yes +++	Yes ++
Incision of gluteus muscles	No	<b>Yes</b>	No
Retraction-section levator plate	No	No	<b>Yes</b>
Potential risks	Lesion of a nerve in the sacro-spinal lig.(Shafik 2007)	<b>Sacro-iliac joint instability</b>	<b>Lesion of levator plate or of a nerve close to the sacro-spinal ligament</b>

## Treatment of pudendal neuropathy: curative

### Results of surgery

1. Nobody knows which operation is the best !!!
2. Results: 60 % on pain, urinary and anal incontinence
3. 3 to 24 months to obtain the final result
4. Possible side effects like increase of pain, incontinences...
5. Specific risks of differents approaches:  
 - transgluteal: sacro-iliac joint instability  
 - transischiorectal: lesion of levator plate or of a nerve close to sacro-spinal ligament

## Treatment of pudendal neuropathy : palliative

1. Drugs: Lyrica®, Neurontin®, Rivotril®...
2. Thermocoagulation: pulsed radiofrequency
3. Sacral neuromodulation

## Don't put current on damaged cables !

### Hypothesis:

J. Beco: *BMC Surg* 2004, **4**(1):15

The results of the pudendal nerve decompression seem to be equivalent to these of neuromodulation [39] and the procedure is far less expensive because there is no need for a special material. If this study is confirmed by others, the treatment of the neuropathy should be done before any trial of neuromodulation. In fact it is logical to repair the electric cable before enabling the current to pass.

### Confirmation:

Antolak SJ, Jr., Antolak CM: **Failed Sacral Neuromodulation: Simple Tests Demonstrate Pudendal Neuropathy. A Case Series.** *J Pelvic Med Surg* 2006, **12**:35-40.

Australian Association of Vaginal and Incontinence Surgeons (AAVIS)  
Keynote Speaker: Jacques Beco M.D.  
How can we win the war against pudendal neuropathy ?

How can we win the war against  
pudendal neuropathy ?

1. Be open mind; don't forget to « think pudendal »
2. Complete evaluation of the patient (before and after each treatment)
3. Urgent need for well designed studies for each step of the management (diagnosis and treatment)

If you want to use data or images from this presentation use  
this reference as citation:

**Beco J: How can we win the war against pudendal neuropathy ?  
[abstract]. *Pelviperrineology* 2008, 27(2):69.**

**More informations :**  
<http://www.pudendal.com>



**AAVIS**  
Australian Association of Vaginal  
Incontinence Surgeons



**IPFDS**  
International Pelvic Floor Dysfunction  
Society

**10<sup>th</sup> AAVIS Annual Scientific Meeting**  
**International Pelviperineology Congress**  
**AAVIS-ICOPF-IPFDS Joint Meeting**  
**Padua-Venice (Italy) - September 30<sup>th</sup> - October 4<sup>th</sup> 2008**

**ABSTRACTS**

**PODIUM PRESENTATIONS**

**Outpatient mid-urethral TFS sling operation  
- a documentary of day surgery in Women's Clinic  
LUNA. (1)**

Y Sekiguchi, M Kinjyo, H Inoue, H Sakata and Y Kubota  
Yokohama, Japan - *E-mail: dumbo-ys@d9.dion.ne.jp*

The TFS (Tissue Fixation System) is a new "minisling" device with a one-way tightening system. We will demonstrate the management of outpatient mid-urethral TFS sling operation in detail in a free-standing outpatient facility.

**Materials and Methods:** Patients were given hydroxyzine hydrochloride 25mg and atropine sulfate 0.5mg i.m. and diclofenac sodium 50mg p.r. before operation. The operations were performed under local anesthesia(LA), using 1% xylocaine 10ml + physiologic saline 40ml+vasopressin 10units. Patients under 70 years were given midazolam 2.5mg additionally. The LA was injected at the sites of the surgery: anterior vaginal wall, peri urethral spaces and below the pubic symphysis, into the tissues behind the perineal membranes (urogenital diaphragm). The mid-urethral TFS sling operation is identical to the first part of a midline 'tension-free tape' operation. A full thickness midline incision was made into the vagina from just below the urethral meatus to midurethra. The vagina was dissected off the urethra with dissecting scissors, and the dissection was carried a few millimeters beyond the perineal membrane (urogenital diaphragm), the space created being just sufficient for the passage of the applicator. The applicator was placed into the dissected space, and triggered to release the TFS anchor. The tape was pulled with a short sharp movement to 'set' the prongs of the anchor into the tissues. Adequate 'gripping' of the anchor was tested by pulling on the free end of the tape. The procedure was repeated on the contralateral side. Taking care to pull in the axis of the anchor's base, the tape was tensioned over a urethra distended by an 18G Foley catheter just sufficiently without indenting it, and the free end cut. The vaginal hammock fascia and the external ligamentous attachment of the external urethral meatus were now tightened with 2-0 Dexon sutures.

**Results:** We performed 37 mid-urethral TFS sling operations for "Genuine stress Incontinence" (GSI) proven by pre-operative urodynamic testing. All patients were discharged the same day. Mean operating time including administration of LA was 22.9 minutes (15-43). Mean blood loss was 14.6 ml. Four patients who could not pass urine within 8 hours were discharged with an indwelling Foley catheter, but passed urine normally within 48 hours. Cure rate at 6 months was 91% (34 /37). The 3 failed cases were cured with another TFS midurethral sling- inserted at 3 months.

**Conclusion:** TFS mid-urethral sling operation is a simple effective procedure, and can be done without difficulty in a free standing clinic as an outpatient.

**Mechanical aspects of different tapes in incontinence surgery - Are requests according to Amid I classification enough? (2)**

A Niesel, A Rohne, M Hanschmann  
Preetz, Germany - *E-mail: a.niesel@klinik-preetz.de*

**Background:** Macroporous and monofil tapes are a request for Amid I classified grafts in mesh supported incontinence surgery. There is consensus, that low - weighted materials are preferable. The aim of this study was to evaluate mechanical characteristics of different tapes as they are thought to play an important role in e.g. the causation of erosion and inflammation.

**Methods:** The physical characteristics of six different tapes (TVT, Uretex, Monarc, Serasis PP, Serasis PA, IVS ) are compared with each other. The subjects are: weight, breaking strength, flexural rigidity, strain, thickness, width with and without tension, pore content, area of the pores and diameter of the threads. Static and dynamic properties were tested under "dry" lab conditions.

**Result:** All tapes consist of Polypropylen (PP). One graft is a partially resorbable material out of PP, polyglycolacid (PGA) and ε caprolacton (PCL) as components of a monofilament thread. After 120 days PGA and PCL are absorbed. There is a wide range concerning the mechanical characteristics of the different tapes. The partial resorbable tape features low flexural rigidity ( 8 mg after resorption. Range of other tapes: 3- 71 mg ) without reduction of breaking strength ( 80 N. Range: 50- 70 N ). According to absorption of PGA and PCL the tape loses half of its weight ( 0,41 g/ mε , Range: 0,57- 1,98 g/ mε ). The smooth surface allows adjustability until to 48 hours postoperative in preliminary clinical tests.

**Conclusion:** Beside Amid I category a number of parameters are likely to affect the ability of a synthetic material to act as the perfect graft. A partial resorbable tape is supposed to have advantages like weight reduction, monofilament surface during critical postoperative phase, masking the hydrophobic surface of polypropylene and more softness in the tissue.

**Trans obturator tape (TOT) procedure for stress urinary incontinence: results at 4-years follow-up (3)**

F Fusco, GA Tommaselli, F Basilica, F Cutillo, P Affinito,  
M P Arienzo, A D' Afiero  
Naples, Italy - *E-mail: gtommaselli@yahoo.it*

**Objective:** To evaluate the long-term results of transvaginal transobturator tape (TOT) in the treatment of female stress urinary incontinence (SUI). Almost all the studies available in literature report a maximum followup of 1-3 years. Aim of this study is to confirm, on a large sample of patients, that results in term of continence and QoL are maintained over time with a minimum follow-up of 48 months

**Patients and Method:** Out of 197 consecutive women, undergoing TOT for SUI between September 2002 and October 2003,

Type 3: contraction of implant (*Grade 1*: palpation of supportive implant is painless, retraction moderate and asymptomatic, arm or body of the prosthesis is palpable but not thickened, *Grade 2*: retraction is moderate (less than about 30%) and/or without many symptoms, palpation may be sensitive, prosthesis globally moderately thickened without nodulae, *Grade 3*: important contraction (more than 50%) and/or painful palpation with localized thickening of the implant, 3A - important contraction, moderate symptomatology, 3B - important and symptomatic contraction, *Grade 4*: simple contact of implant is painful ++ even if contraction is not always palpable).

Type 4: erosions due to implant erosions: a) of vaginal fornix, b) urethral erosion, c) bladder, d) rectum, e) other distant).

This classification can only be temporary but distinguishes different types of complications too often mixed up in publications.

## AAVIS KEYNOTE SPEAKER: DR J. BECO

### How can we win the war against pudendal neuropathy? (87)

J Beco

University of Liège, Belgium - *E-mail: jacques.beco@skynet.be*

**Background:** Pudendal neuropathy is one of the seven main defects encountered in Perineology. This defect can induce perineodynia but also gynaecological, urological and colo-proctologic symptoms. Despite growing evidence of its importance this diagnosis is still rarely made and effective treatments available more rarely used. The aim of this lecture is to improve the management of those patients who suffer from this quite frequent and very aggressive illness.

**Methods:** To win a war it is necessary to perfectly understand who your enemy is, how it looks like, how you can differentiate it from your other enemies and what are its weaknesses.

Strategy is of uppermost importance. Wrong ways and false friends must be avoided. Because it is a new enemy, changing its look like a chameleon, we must be very open mind and modest to win this war.

**Results:** Urge and stress urinary incontinences, urgencies, frequency, painful bladder, dysuria, abacterial prostatitis, sexual arousal syndrome, proctalgia fugax, painful ejaculation, impotence, pain while sitting, vulvodinia, anal incontinence, dyspareunia, dyschesia... can be induced by pudendal neuropathy. Don't forget to think "pudendal"!

Clinical examination is the first and most important part of the diagnosis. Besides the classical examination of the perineum, it is necessary to search at least for the 3 clinical signs of pudendal neuropathy, for an abnormal perineal descent (using a Perineocaliper®), for other neuralgias and for pelvic floor muscle trigger points.

EMG with PNTML, warm and cold detection thresholds, Doppler of the pudendal arteries, MRI of the ischio-rectal fossae and of the lombo-sacral spine, can be helpful to confirm the diagnosis.

The main steps of the treatment are life style changes, painkillers, physiotherapy (with trigger point treatment), pudendal nerve blocks, surgical pudendal nerve decompression and neuromodulation.

**Conclusion:** In front of a functional perineal trouble, be open mind; don't forget to think "pudendal"!

## FISTULAS AND FLAPS

### Complicated urinary fistula. (88)

B Liedl

Munich, Germany - *E-mail: bernhard.liedl@med.uni-muenchen.de*

Successful management for complicated urinary fistula starts with sufficient diagnosis of location of the fistula (Ureter, bladder, urethra, rectum or combinations), the underlying causes and accompanied conditions (e.g. post radiotherapy, tumor recurrence, previous surgery, coloproctologic disease) and evaluation of the tissues surrounding the fistula tract. Small vesicovaginal fistulas with sound elastic surrounding tissue usually can be closed transvaginally: excision of the fistula tract, closing the bladder by inverting sutures, suturing the pubocervical fascia and the vaginal wall by everting running suture with the aim to approximate broad healthy wound planes without tension. If the wound edges cannot

be sutured without tension or if tissue defects are present, tissue transfer is necessary. Bladder flaps, interposition of bowel, omentum majus or peritoneal flaps can be helpful. By vaginal route a Martius-flap with skin-island can be interposed. Concomitant lacerations of ureter or rectum possibly need ureter reimplantation or rectal surgery. De-epithelizing and closure of the vagina partially or totally can be an option in old, sexually non active women. Supravescical derivation (Conduit, pouch) are options, if fistula closure is not possible.

### Anorectal fistulas and biological prostheses. (89)

R Scherer

Berlin, Germany - *E-mail: r.scherer@waldfriede.de*

**Purpose:** In 2006 the anal fistula plug technique was introduced in the treatment of transsphincteric anal fistulas. Since the results were encouraging, the technique was adapted to the treatment of rectovaginal fistulas.

The surgical technique and the preliminary results were presented.

**Methods:** 15 patients with rectovaginal fistulas were included prospectively for the repair with biological meshes. Feasibility, complications and reinterventions were assessed.

**Results:** 15 patients with rectovaginal fistulas were treated with a biological mesh in a special surgical technique. No intraoperative or postoperative complications were observed. At a mean follow up of 7.9 months, 12 of 15 patients healed, in 3 of 15 cases a recurrence was observed.

**Conclusions:** The repair of rectovaginal fistulas with biological meshes is a new procedure with good first results.

The long term recurrence rate must be awaited.

### Imaging of fistula-in-ano. (90)

G Santoro

Treviso, Italy - *E-mail: giulioasantoro@yahoo.com*

A variety of imaging techniques have been used to evaluate fistula-in-ano and perianal sepsis over the years. Preoperative identification of all loculate purulent areas and definition of the anatomy of the primary fistulous tract, secondary extensions, and the internal opening plays an important role in adequate planning of the operative approach in order to prevent recurrence after surgical treatment, and to minimize iatrogenic damage of anal sphincters. Over the last two decades, endoanal ultrasonography (EAUS) and magnetic resonance imaging (MRI) have been demonstrated to be very helpful diagnostic tools in accurately assessing fistulas characteristics. When considering the comparison between EAUS and MRI it is worthwhile focussing on exactly what it is that sonography does well. It is well-established that ultrasound generally best images structures that are close to the transducer surface, and the higher the frequency of the transducer, the more this condition will apply. In particular, using modern 16 MHz transducers, EAUS is particularly well-suited to identification of the internal opening, because it usually lies right at the probe surface. Anal endosonography facilitates quick and easy diagnosis of intersphincteric fistulas and abscesses because of the high spatial resolution of the technique. Transsphincteric fistulas are revealed by tracks that cross the external sphincter to reach the ischioanal fossa. The further they are from the anal canal, the less-well extensions are visualised by EAUS. This is because the depth of penetration of the ultrasound beam is limited, especially at higher frequencies. Also, EAUS has great difficulty to determine if a collection is supra- or infra-levator because the levator plates lies in the same plane as the ultrasound beam. Moreover EAUS cannot reliably distinguish infection from fibrosis since both appear hypoechoic. This causes particular difficulties in patients with recurrent disease since infected tracts and fibrotic scars are frequently combined. Injection of hydrogen peroxide into the external opening may help to clarify the course of patent tracts. The advent of high-resolution three-dimensional EAUS (3D-EAUS), constructed from a synthesis of standard 2D cross-sectional images, promise to improve the accuracy in preoperative fistula classification. When examining anal fistulas, the operator can trace the pathway of a tract by reviewing the entire series of ultrasound images reconstructed along all planes desired.

The success of MRI for pre-operative classification of fistula-in-ano is a direct result of its sensitivity for tracks and abscesses combined with high anatomic precision and ability to image in surgically relevant planes. The major advantage of MRI over EAUS is the facility with which it can image extensions (transsphincteric,