

Ultrasound-guided Procedures for Pelvic Pain

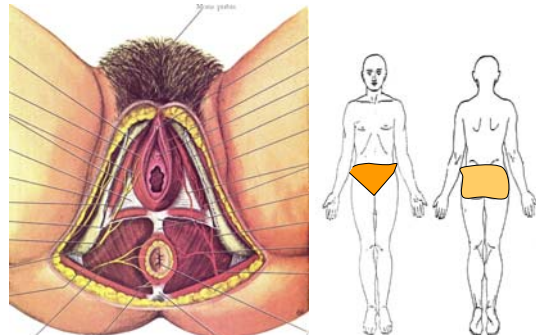


Philip Peng MBBS FRCP
Department of Anesthesia, University of Toronto
Toronto, Canada
The Aix-Lyon-Strasbourg Pelvic Pain Diagnostics and Procedures Meeting
Aix-en Provence, France
Jan 8-9, 2009

Ultrasound-guided Procedures for Pelvic Pain

The Aix-Lyon-Strasbourg Pelvic Pain Diagnostics and Procedures Meeting

Chronic Pelvic Pain



The Aix-Lyon-Strasbourg Pelvic Pain Diagnostics and Procedures Meeting

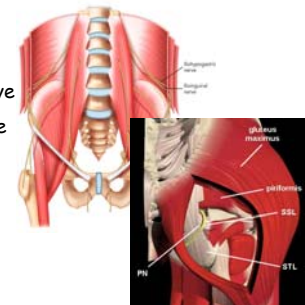
Chronic Pelvic Pain

Border nerve syndrome

- Ilioinguinal nerve
- Iliohypogastric nerve
- Genitofemoral nerve

Piriformis syndrome

Pudendal neuralgia



The Aix-Lyon-Strasbourg Pelvic Pain Diagnostics and Procedures Meeting

Pudendal Nerve Block

Transvaginal route

Transperineal route

Transgluteal route

- Electrophysiological
- CT
- Fluoroscopy
- US

The Aix-Lyon-Strasbourg Pelvic Pain Diagnostics and Procedures Meeting

Feasibility of Real-Time Ultrasound for Pudendal Nerve Block in Patients with Chronic Perineal Pain

Ayman Rofa'el, M.D., Philip Peng, M.B.B.S., F.R.C.P.C., Ihab Louis, M.D., and Vincent Chan, M.D., F.R.C.P.C.

Reg Anesth Pain Med 2008; 33:139-145

The Aix-Lyon-Strasbourg Pelvic Pain Diagnostics and Procedures Meeting

RCT US vs. XR

Sensory block

- Time
- Sciatic N spill
- Visualization
- Pudendal nerve
- Pudendal Artery
- Sciatic nerve
- STL
- SSL

The Aix-Lyon-Strasbourg Pelvic Pain Diagnostics and Procedures Meeting

RCT US vs. XR

	Fluoroscopy	Ultrasound
Sensory block	Ø block in 2/13	All blocked
Time (SE)	3.4 ± 0.3 min	7.5 ± 0.5min
Sciatic N spill	3/13	2/13

The Aix-Lyon-Strasbourg Pelvic Pain Diagnostics and Procedures Meeting

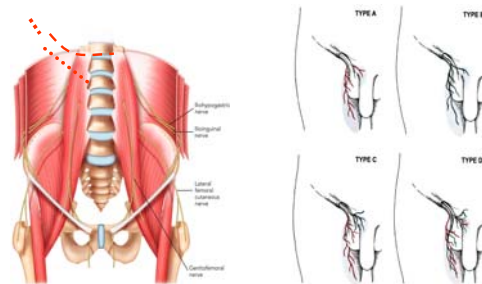
RCT US vs. XR

Visibility	Good	Fair	Poor
Pudendal A	5	8	0
Pudendal N	3	5	5
Sciatic N	8	2	1
STL	7	6	0
SSL	8	5	0

<1cm from ischial spine: 38%; > 1cm from ischial spine: 62%

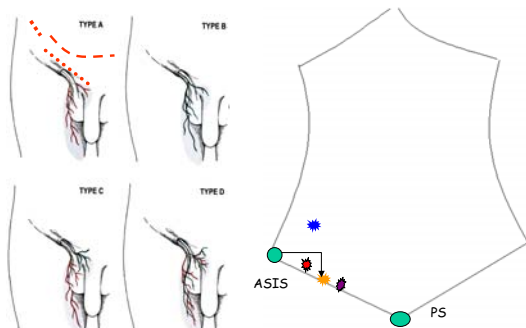
The Aix-Lyon-Strasbourg Pelvic Pain Diagnostics and Procedures Meeting

Border Nerves Syndromes

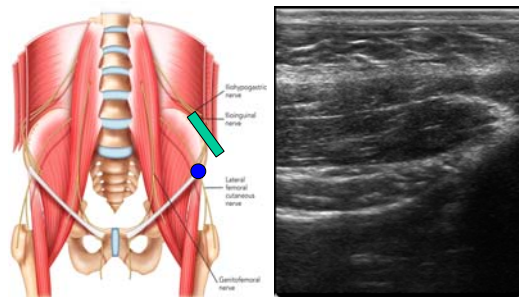


The Aix-Lyon-Strasbourg Pelvic Pain Diagnostics and Procedures Meeting

Border Nerves Syndromes

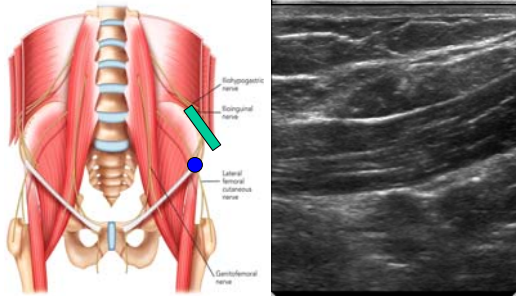


Ilioinguinal & Iliohypogastric Nerve



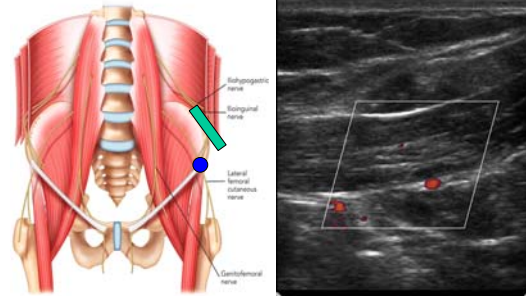
The Aix-Lyon-Strasbourg Pelvic Pain Diagnostics and Procedures Meeting

Ilioinguinal & Iliohypogastric Nerve



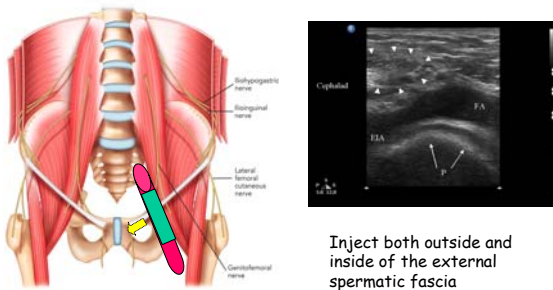
The Aix-Lyon-Strasbourg Pelvic Pain Diagnostics and Procedures Meeting

Ilioinguinal & Iliohypogastric Nerve



The Aix-Lyon-Strasbourg Pelvic Pain Diagnostics and Procedures Meeting

Genitofemoral Nerve



Inject both outside and inside of the external spermatic fascia

The Aix-Lyon-Strasbourg Pelvic Pain Diagnostics and Procedures Meeting

Genitofemoral Nerve

Anatomic Variability of the Ilioinguinal and Genitofemoral Nerve: Implications for the Treatment of Groin Pain

Matthias Rab, M.D., Johannes Ehmer, and A. Lee Dellon, M.D. *Plast Reconstr Surg* 2001

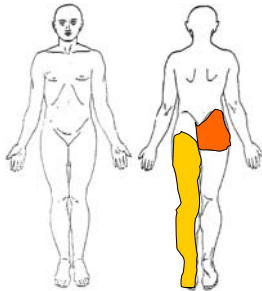
Applied Anatomy of the Genital Branch of the Genitofemoral Nerve in Open Inguinal Herniorrhaphy

Wan-Cheng Liu¹, Tien-Hua Chen^{2,3}, Jia-Fwu Shyu³, Chien-Hsing Chen³, Chung Shih³, Jaang J. Wang³, Sung-Pao Kung², Wing-Yui Lu², Chew-Wun Wu³ and Jiang-Chuan Liu³

Eur J Surg 2002

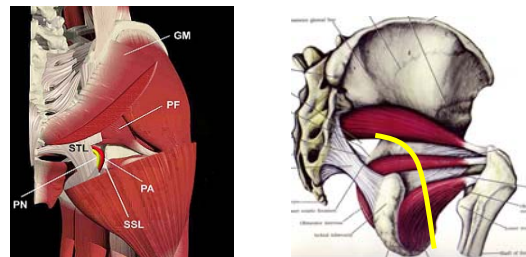
The Aix-Lyon-Strasbourg Pelvic Pain Diagnostics and Procedures Meeting

Piriformis Muscle.



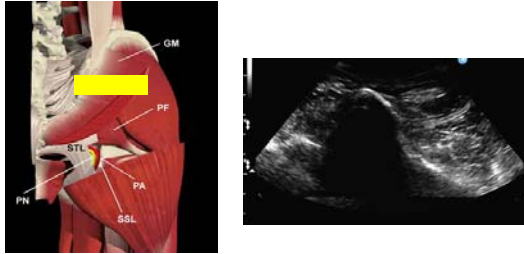
The Aix-Lyon-Strasbourg Pelvic Pain Diagnostics and Procedures Meeting

Anatomy



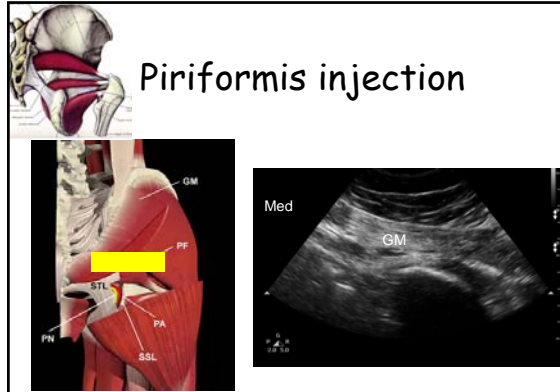
The Aix-Lyon-Strasbourg Pelvic Pain Diagnostics and Procedures Meeting

Piriformis injection



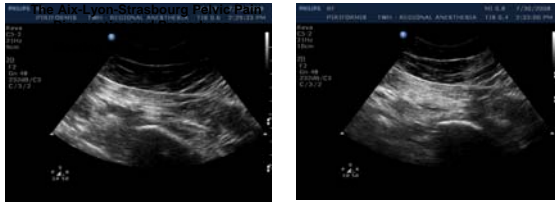
The Aix-Lyon-Strasbourg Pelvic Pain Diagnostics and Procedures Meeting

Piriformis injection



The Aix-Lyon-Strasbourg Pelvic Pain Diagnostics and Procedures Meeting

Piriformis injection



The Aix-Lyon-Strasbourg Pelvic Pain Diagnostics and Procedures Meeting

